

# TRANSFORMING SMILES: A CASE SERIES ON THE IMPLEMENTATION OF DIGITAL SMILE DESIGN

Rohan Pramod Bhave <sup>1</sup>, Ajay Vyankatesh Sabane <sup>2</sup>,  
Bhagyashree Gurunath Kalsekar <sup>3</sup> and Mehul A. Shah <sup>4\*</sup>

<sup>1</sup> Post Graduate Student, Department of Prosthodontics and Crown & Bridge, Bharati Vidyapeeth (Deemed to be University) Dental College and Hospital, Pune, Maharashtra, India.

<sup>2,3</sup> MDS, Professor and Head, Department of Prosthodontics and Crown & Bridge, Bharati Vidyapeeth (Deemed to be University) Dental College and Hospital, Pune, Maharashtra, India.

<sup>4</sup> MDS, Assistant Professor, Department of Public Health Dentistry, Bharati Vidyapeeth (Deemed to be University) Dental College and Hospital, Pune, Maharashtra, India.

\*Corresponding Author Email: [mehul.shah@bharatividyaapeeth.edu](mailto:mehul.shah@bharatividyaapeeth.edu)

DOI: [10.5281/zenodo.13120657](https://doi.org/10.5281/zenodo.13120657)

## Abstract

Smile designing has recently evolved significantly, shifting from traditional analogue methods to advanced digital techniques. In the past, practitioners would hand-draw on printed photos to demonstrate potential outcomes to patients. Although effective at the time, this approach lacked precision and flexibility. This case report series presents two instances of smile rehabilitation in patients with severe fluorosis, tooth discoloration, and shape alteration following orthodontic therapy. A fully digital approach was employed, utilizing two different scanners and software for smile design.

**Keywords:** Traditional Analogue Methods, Advanced Digital Techniques, Orthodontic Therapy, Tooth Discoloration.

## INTRODUCTION

A person's ability to convey a variety of emotions through their smile and the way their lips and teeth move together frequently indicates how well they will get along in society. [2] The demand for beautiful smiles has become a phenomenal trend that shows no sign of diminishing. [1] The introduction of digital technologies into dentistry has caused a paradigm shift in recent years, completely changing the way dental practitioners approach smile design. The innovative method known as Digital Smile Design (DSD) combines the artistic skills of dentists with state-of-the-art digital instruments to provide patients individualized, aesthetically beautiful smiles.

A cosmetic study of the assembly—face, smile, periodontal tissue, and teeth—is possible through the planning process of digital smile design (DSD). [3] Using anatomical axes and the face's reference lines as a map, an examination of digital photos taken both inside and outside the mouth can be used to determine the ideal gingival shape, contour, and alignment of the teeth. Because it permits a final dental outline that illustrates the connection between the preoperative circumstances and the ideal design, as well as serving as a guide for the diagnostic wax-up and, by extension, the mock-up, this increases treatment predictability. [3,4]

Recently, smile designing has seen significant advancements, transitioning from physical analogue methods to sophisticated digital techniques. Initially, practitioners used hand-drawing on printed photos to communicate and illustrate potential outcomes to patients. This method, while effective for its time, was limited in its

precision and flexibility. [5] Today, the field has embraced digital smile design (DSD), which allows for highly accurate and detailed simulations. Early digital designs were primarily 2D, involving basic computer software to create visual representations of the proposed dental changes. However, with the advent of advanced 3D technology, DSD has evolved dramatically. [5]

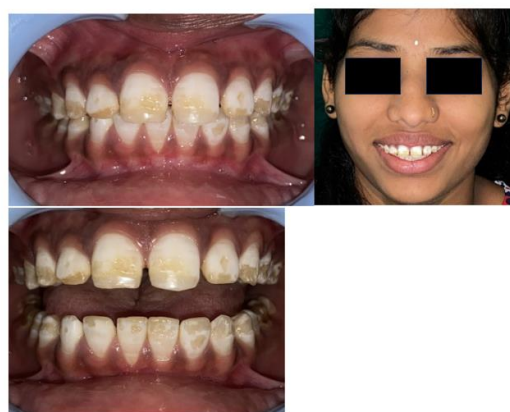Modern DSD software enables practitioners to create comprehensive three-dimensional models of a patient's smile. These digital models are not only visually accurate but also interactive. They can be manipulated easily, allowing for adjustments and refinements that ensure both aesthetic and functional needs are met. The ability to make real-time edits and visualize the effects immediately is a significant improvement over the analogue methods. This flexibility helps in achieving a more precise and patient-specific outcome. [5]

The progression from 2D to 3D digital smile design has also enhanced patient communication and satisfaction. Patients can now see a realistic preview of their post-treatment smile, making it easier to set expectations and make informed decisions. Additionally, the integration of digital technology streamlines the entire process, from initial consultation to final treatment, making it more efficient and accurate. [5]

In summary, the evolution from hand-drawn designs on printed photos to sophisticated 3D digital models represents a major leap in smile designing. This transformation enhances the ability to balance aesthetic goals with functional needs, offering a more reliable and satisfying experience for both practitioners and patients. [5]

According to Peter Dawson, creating a peaceful and stable masticatory system, where the teeth, tissues, muscles, skeletal structures, and joints all function in harmony, is the aim of an aesthetic makeover.[1] The following case report series demonstrates two such cases where the smile rehabilitation was done in a patient with severe fluorosis and discolouration of teeth and a shape alteration post orthodontic therapy using the fully digital approach using two different scanners and softwares for smile designing.

**Case report 1:** A female patient of age 19 years reported to the Department of Prosthodontics, Bharati Vidyapeeth Dental College, Pune with a chief complaint of yellowish-brown discolouration on teeth since the past few years. On clinical examination, the patient was found to have Dental fluorosis classified to be “moderate” according to the classification by Dean.



**Fig 1: Pre-operative photographs**

The other problem areas diagnosed in the case were generalized spacing, shift of the dental midline towards the right side, all of which led to the patient having a compromised and unsatisfactory smile.

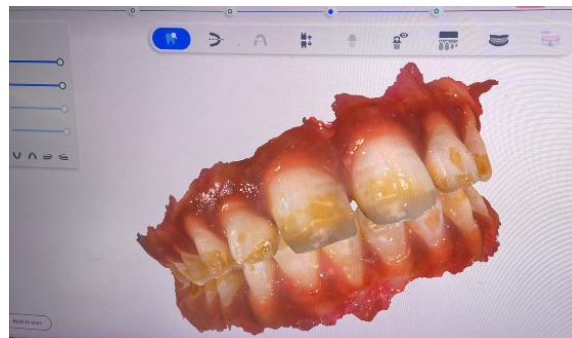
Diagnostic impressions were recorded using irreversible hydrocolloid and study casts were poured and articulated for evaluation. Various treatment options were discussed including orthodontic therapy, conservative treatment using composite build up, laminate veneers. However, the patient was not ready to undergo orthodontic therapy and wanted a treatment option that was long lasting, but fast.

Keeping into consideration the patient's demands, a digital smile design treatment was planned on the patient. Due to financial constraints of the patient as well as the condition of the enamel, E-max full veneer crowns were planned in the maxillary region in the tooth number 13,12,11, 21, 22, 23.

The patient was explained about the entire procedure as well as the expected treatment outcome. The mandibular teeth were not involved in the process due to financial constraints and the mandibular anteriors were less conspicuous upon smiling.

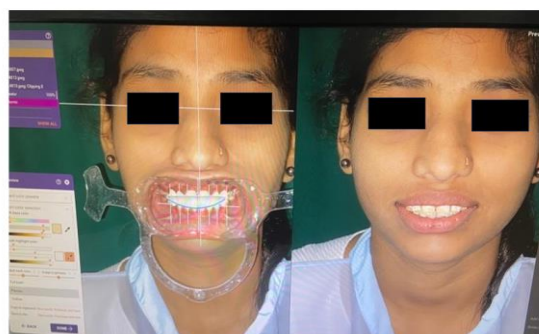The workflow was as follows:

STEP 1: Extraoral photographs, one normal and one wide smile were taken along with a retracted smile. On the same day, pretreatment intraoral scans of both the arches were recorded along with the scan of the bite using Shining 3D scanner.



**Fig 2: Intra oral scan of the maxillary and the mandibular teeth and the centric bite**

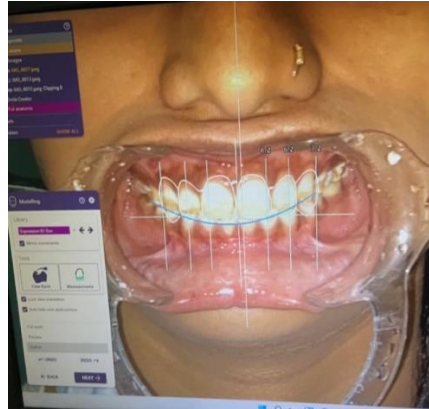
STEP 2: SMILE ANALYSIS: The photographs of the patient and the intraoral scan were superimposed onto one another on the Exocad software using canine tips as a guide, digital facebow record using interpupillary line as a guide was taken for orientation of the maxillary arch.



**Fig 3: Orientation plane of maxillary arch**

The problems of the patient were critically analyzed, which included broad width of the laterals, spacing, buccally tipped 12 and 22 and blunt tips of the canines.

STEP 3: SMILE SIMULATION: A smile simulation was carried out by increasing the length of the centrals and laterals and curving in the canines. The lower lip line was used as a guide to set up the incisal edge positions of the anterior teeth.

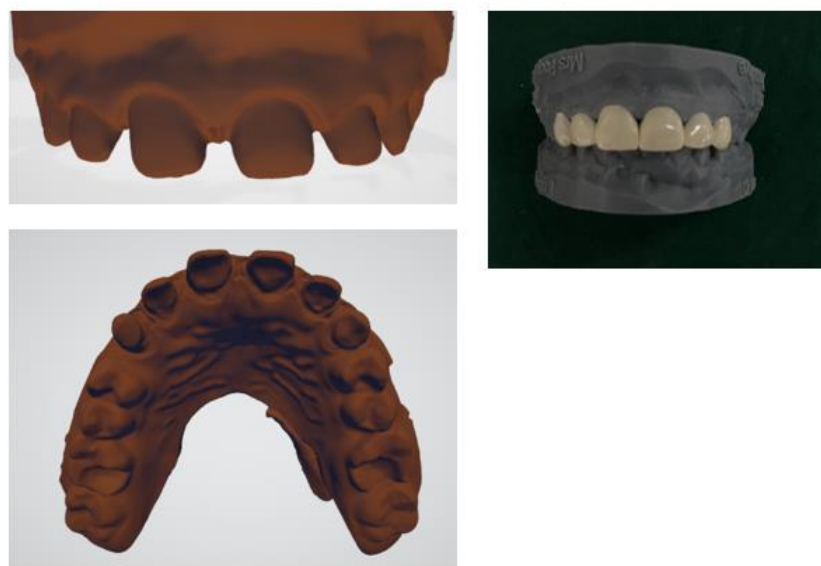

**Fig 4: Designing of the smile curve from canine to canine**

STEP 4: 3D printing of the of the designed model is completed.

STEP 5: An Addition silicone putty is adapted on the 3D printed cast to make a template for simulating the final outcome in the patient. The patient was satisfied with the expected outcome.

STEP 6: Tooth preparations for full coverage porcelain crowns were carried out with a shoulder margin with equi gingival placement and a post-preparation intra oral scan was recorded. The patient was temporized using the same putty index. The scan was sent to the laboratory for fabrication of CAD/CAM temporary crowns.



**Fig 5: Tooth preparation scan showing tooth preparation for a full crown E-max prosthesis from canine to canine and fabrication of CAD/CAM temporary crowns**

This step was carried out to further evaluate the treatment outcome and make changes in the final E-MAX crowns if needed.

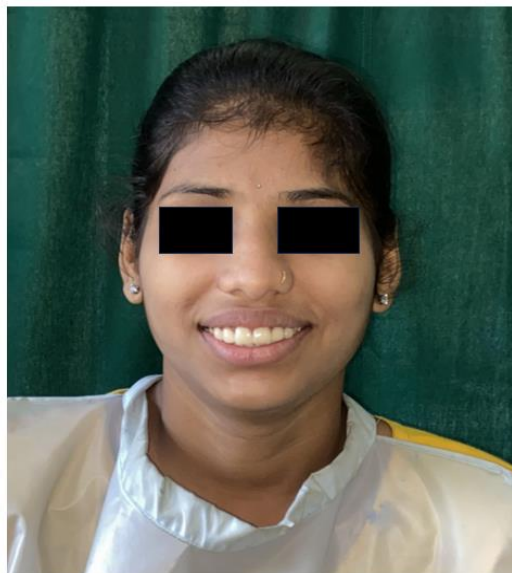STEP 7: The CAD/CAM crowns were milled and cemented in the patient using a temporary luting cement- RelyX TEMP NE non eugenol cement.

STEP 8: The final minor corrections in the design were made and E-max full crowns were milled and given for bake trial. The changes included minor correction in the incisal line angles.

STEP 9: Bake trial was carried out and evaluation of the anterior guidance and mutually protected occlusion which was previously present in the patient's mouth was checked in the bake trial.

STEP 10: Final glazing and characterization was done.

The crowns were etched using 9% HF followed by application of silane coupling agent and air drying. The teeth were etched using 37% phosphoric acid followed by application of dentin bonding agent. The final cementation of the crowns was done using dual cure resin cement RelyX U 200.



**Fig 6: Final post-operative treatment outcome of the treatment**

### **Case report 2:**

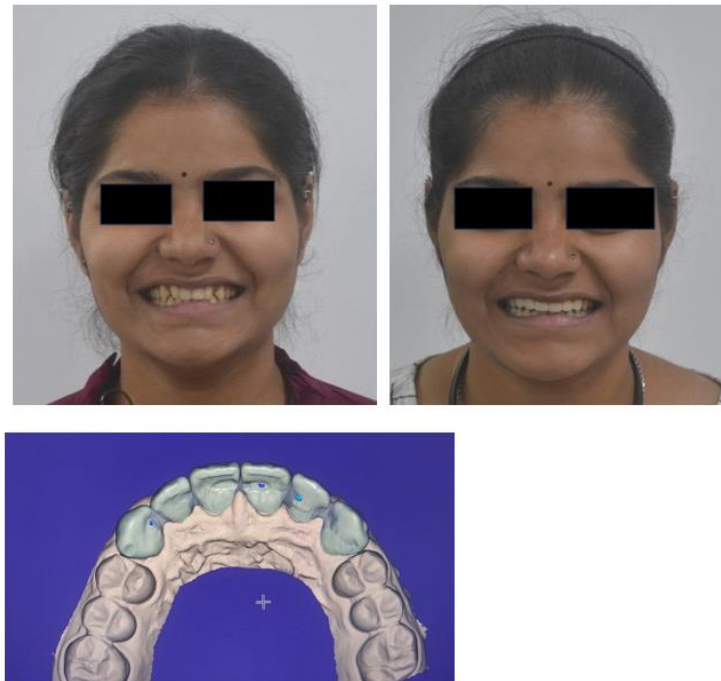
A female patient, age 23 years was referred from the department of Orthodontics and Dentofacial orthopedics post orthodontic therapy of spacing with the concern of diastema between the left and right lateral incisors and canines. Orthodontic correction was not possible due to the defect in tooth anatomy in both the lateral incisors.

Upon clinical examination, 1.5 mm space was seen between the left and right lateral incisors and canines. Patient was suggested a digital smile design procedure from 13 to 33 in order to correct the existing problem.

The digital workflow was modified by combining the STEP 1 and STEP 2 on a single day.

By making the necessary extraoral photographs, the photos were transferred into the 3 shape digital smile design simulation software and a smile simulation was carried out on the same day by designing the smile in front of the patient.

All the other steps were repeated in a similar manner as in case report 1, except that the trios 3 shape scanner was used and the 3shape smile design software was used for designing the smile.



**Fig 7: Pre op and post op pictures of case no 2**

## DISCUSSION

Digital smile designing helps the dentist to plan the treatment conveniently and with minimal need of patient's records and drastic reduction in the number of patient visits. With the advent of this new digital technology, the need for time consuming impressions and abundant use of impression materials and plasters is reduced. Not only does this let the patient visualize the simulated outcome, but also it does encourage the patient for undergoing the necessary treatment especially in cases where the patient is demotivated or skeptical.

In the case 1, the chief complaint of the patient was discoloration of teeth. The patient was diagnosed clinically and other existent problems such as spacings, minor rotations were conveyed to the patient of which she was not quite aware about. After discussing various treatment options, a digital smile design was planned. After taking various photographs intraorally and extraorally, designing was done on the EXOCAD software and shown to the patient followed by a test drive of the result using the addition silicone template. This further boosted the patient's confidence to undergo the treatment. Due to the additive nature of the treatment, and keeping into consideration the age of the patient, intentional endodontic treatment was avoided. Similarly, due to an existing high smile line, gingivoplasty was not recommended to the patient.

The major limitation in the case treatment was the patient's decision of not undergoing prior orthodontic therapy. Due to the same, it was not possible to alter the protrusion of the maxillary teeth beyond a certain limit. The aesthetic outcome could have been better if a prior orthodontic therapy was carried out. The dental to facial midline correction was not possible due to the same reason.

However, in the second case, the problem encountered was primarily orthodontic. The patient underwent Orthodontic therapy for spacing. Due to the anatomical challenges however, it was not possible to improve the smile of the patient using Orthodontic means alone. Hence, a decision to undergo smile designing was made. The challenge in the case was maintaining the tooth position since the case was treated for generalized spacing. A decision to use joint crowns instead of individual crowns or veneers was made due to the problem of space closure post orthodontic therapy. Hence, the added benefit of the joint crown prosthesis was that there was no need of an additional retainer for maintenance of tooth position.

The decision of using zirconia layered with ceramic was made since zirconia, being a stronger material would provide reinforcement needed for the joint crowns and the ceramic layering would provide the necessary aesthetic outcome. The challenging part in the treatment was the tooth preparation to provide a single path of insertion for the joint prosthesis.

In the second case, it was easier for the doctor to communicate the need of treatment as well as give an overview of the treatment outcome by using the 3 shape software. The patient was convinced for the treatment readily as the smile simulation was carried out in the first appointment itself. However, it was found that it was much easier to design the crowns on the EXOCAD software post preparation than the 3 shape software due to operator's and the lab technician's convenience.

The major limitation of the treatment was the position of the connectors. Due to the single path of insertion, the position of the connectors could not be manipulated. However, efforts were made to provide adequate space for interdental gingiva to grow into the spaces between the joint crowns and not compress the interdental papillae.

In the present case series, no impression procedures were carried out manually and hence, not only did the patient comfort improve, but also the fit of the crowns was superior.

In both the case scenarios, due to the financial constraints, lower teeth were not involved in the smile design procedure which could have resulted in superior treatment outcomes.

The entire process lets the patient participate in the treatment planning and thus improves the communication and interaction between the patient and the operator. Certain interdisciplinary procedures like gingivoplasty can also be carried out efficiently if needed in the anterior aesthetic zone by fabricating a stent digitally.

With the advent of new softwares like the 3Shape smile design software, the designing of the smile can now be done on the first appointment itself in front of the patient, without the need of an intraoral scan initially. The use of the software allows the patient to choose from a variety of options from the tooth library which further fastens the process and enhances the visual communication. The final designing of the prosthesis can however be completed using EXOCAD or other software due to the feasibility of the software and designing convenience.

## References

- 1) Dawson PE. Functional occlusion: from TMJ to smile design. St. Louis, Mo.: Mosby; 2007.
- 2) Bhuvaneshwaran M. Principles of smile design. Journal of Conservative Dentistry. 2010;13(4):225.
- 3) 1. Meereis C, de Souza G, Albino L, Ogliaari F, Piva E, Lima G. Digital Smile Design for Computer-assisted Esthetic Rehabilitation: Two-year Follow-up. Operative Dentistry. 2016 Jan 1;41(1): E13–22.
- 4) Coachman C, Calamita M, Sesma N. Dynamic Documentation of the Smile and the 2D/3D Digital Smile Design Process. The International Journal of Periodontics & Restorative Dentistry. 2017 Mar;37(2):183–93.
- 5) Jafri Z, Ahmad N, Sawai M, Sultan N, Bhardwaj A. Digital Smile Design-An innovative tool in aesthetic dentistry. J Oral Biol Craniofac Res. 2020 Apr-Jun;10(2):194-198. doi: 10.1016/j.jobcr.2020.04.010. Epub 2020 Apr 18. PMID: 32373450; PMCID: PMC7193250.